



Cardiac Arrest in a Pregnant Patient Diagnosed with Bochdalek Hernia

Gebe Hastada Kardiyak Arrest ile Tanısı Konulan Bochdalek Hernisi

Bochdalek Hernia in a Pregnant Patient

Pınar Karabacak, Hacı Ömer Osmanlıođlu, Berit Gökçe Ceylan, Mehmet Ali Yađlı, Mustafa Kemal Yıldırım
Department of Anesthesiology and Reanimation, Suleyman Demirel University Faculty of Medicine, Isparta, Turkey

This paper was presented as poster at the 20th International Intensive Care Symposium, 8-9 May 2015, Istanbul, Turkey

Özet

Bochdalek hernisinin gebeliđin 8. Haftasında plöroperitoneal membranın septum transversum ile füzyonundaki bozukluk sonucu oluđu düşünölmektedir. Olguların çođunluđu dođduktan sonra solunum sıkıntısı ile klinik bulgu verir ve eriřkin yařa kadar semptomsuz seyir göstermesi oldukça nadir bir durumdur. Hamilelikle birlikte olan yetiřkin bochdalek hernisi oldukça nadirdir. 39 yařında 24 haftalık gebe hasta acil servise epigastrik ađrı ve kusma nedeniyle bařvuruyor. Hastaya ađrısı için abdominal Ultrasonografi (USG) planlandı ve iřlem yapılırken hastada aniden kardiyak arrest geliřti. Bu olguda geınç hamile bir kadında kardiyak arrest ile tanısı konulan konjenital diyafragma hernisi sunulmuřtur.

Anahtar Kelimeler

Bochdalek Hernisi; Kardiyak Arrest; Gebelik

Abstract

Bochdalek hernia is thought to be the result of a defect of the pleuroperitoneal fold and the septum transversum fusion in the 8th week of gestation. The majority of these patients present with respiratory distress after delivery; asymptomatic progress until adulthood is an extremely rare clinical occurrence. The adult form of a Bochdalek hernia accompanying pregnancy is a rare entity. A 39-year-old, 24-week pregnant patient applied to Emergency service with epigastric pain and vomiting. Abdominal ultrasonography was planned due to the abdominal pain; sudden cardiopulmonary arrest occurred during the procedure. In this case report, congenital diaphragmatic hernia in a young pregnant woman who underwent cardiac arrest is presented.

Keywords

Bochdalek Hernia; Cardiac Arrest; Pregnancy

DOI: 10.4328/JCAM.4675

Received: 31.05.2016 Accepted: 19.07.2016 Printed: 01.09.2016

J Clin Anal Med 2016;7(5): 746-8

Corresponding Author: Pınar Karabacak, Department of Anesthesiology and Reanimation, Suleyman Demirel University Faculty of Medicine, Isparta, Turkey.
GSM: +905056846286 F.: +90 2462237831 E-Mail: drpinara@gmail.com

Introduction

Bochdalek hernias are congenital diaphragmatic defects resulting from a failure of fusion of the posterolateral diaphragmatic foramen. A Bochdalek hernia in a newborn usually causes severe respiratory distress and high mortality rates. Bochdalek hernias presenting after the neonatal period have non-specific thoracic and abdominal symptoms. Bochdalek hernia occurring in an adult is a rare occurrence. Symptomatic Bochdalek hernias in adults are infrequent; they may lead to gastrointestinal dysfunction or severe pulmonary disease [1,2]. A symptomatic diaphragmatic hernia during pregnancy is a rare but potentially dangerous condition. The case reported here is of a young pregnant woman with a congenital diaphragmatic hernia who presented with pain and vomiting and underwent cardiac arrest [3].

Case Report

A 39-year-old, 24-week pregnant patient presented at the Emergency service with epigastric pain and recurrent vomiting. In the anamnesis there were no comorbidities; the patient had two healthy children and had not been attending regular prenatal examinations during this 3rd pregnancy. Her vital signs were stable and the gynecological examination was normal on admittance. On obstetric ultrasonography, a single fetus was seen with normal amniotic fluid and placenta. There was no history of trauma or disease and no abnormality was diagnosed during prenatal visits. Cardiopulmonary arrest occurred during abdominal ultrasonography. After 10 minutes of CPR, the patient was transferred to ICU, intubated, and mechanical ventilation was initiated.

The mechanical ventilation settings were 6ml/kg tidal volume and 5cm H₂O PEEP with a plateau pressure >30cm H₂O. On the abdominal USG applied in the ICU, free fluid and free air were seen. No heart pulsation was determined on the fetal USG. As the patient had low blood pressure, the fluid therapy was increased by starting inotropic therapy.

The chest x-ray exhibited free air trapped in the left lung basal area and the USG showed free fluid in the abdomen (Figure 1). As the air-fluid level was seen on the lateral decubitus abdominal radiograph, the patient was admitted for emergency surgery with suspected perforation. A Bochdalek hernia was seen in the diaphragm during the operation. It was seen to be strangulated by the defect having passed the spleen and stomach; a gastric and splenic perforation was diagnosed in the mediastinum. Primary gastric and diaphragmatic repair was made and a splenectomy was performed. The ex fetus was delivered. A chest tube was attached to the patient's left lung. Postoperatively the patient was transferred to the ICU and empirical antibiotic therapy was started. The inotropic therapy was continued for 2 days and on the 2nd day, as blood pressure values improved, the inotropic therapy was gradually decreased and terminated. In the postoperative neurological examination of the patient in the ICU, the GCS was 3, so on the 2nd day, brain CT was applied to the unconscious patient. Generalized oedema and ischemic areas were determined on the CT. Anti-oedema therapy was started. Ischemic encephalopathy was diagnosed. Although the brain oedema was seen to decrease on the CT taken while the patient was still unconscious, the oedema continued. Microbiologic cultures were taken on the 7th day because of an increase

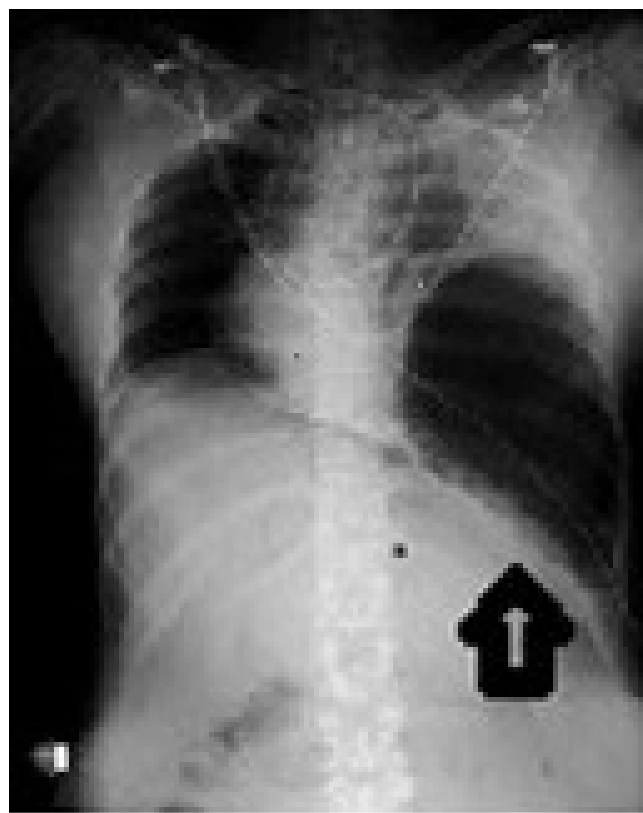


Figure 1. The patient's chest x-ray exhibited free air trapped in the left lung basal area.

in fever and pulmonary secretions. Bilateral infiltrations were determined on pulmonary radiographs and empirical treatment of Meropenem 3×1 gr and Linezolid 2×600 mg was started. Spontaneous respiration was insufficient so a tracheotomy was performed on the 10th day of ICU. On the 14th day, the antibiotics were terminated as the patient had no findings of infection and brain oedema was seen to have decreased on the CT. The GCS evaluation was 6. Mechanical ventilation support was continued.

On the 30th day of hospitalization, fever increased to 38.4°C, hypotension was determined, and a new left-sided infiltrate was identified. A bronchoscopy was performed with bronchoalveolar lavage and the culture material was sent for quantitative culture. The antimicrobial therapy was changed according to the hospital's antimicrobial protocol. On the 31st day of hospitalization, the patient also developed hypotension requiring repeated fluid boluses and the administration of vasopressors. She died from sepsis due to pneumonia.

Discussion

A diaphragmatic defect may be located in the esophageal hiatus (hiatal hernia), near the hiatus (paraesophageal), retrosternal (Morgagni), or posterolateral (Bochdalek). Left-sided lesions account for 70-90% of cases. Consistent with these reports, the current patient had a left-side defect. The majority of these patients present with respiratory distress after delivery. Asymptomatic progress until adulthood is an extremely rare clinical occurrence. Symptomatic Bochdalek hernias are common in the neonatal period and early pediatric age groups, but are relatively rare outside of this range. Adult Bochdalek hernias more commonly present with gastrointestinal symptoms than with pulmonary symptoms. The complaint of this patient on first

presentation was epigastric pain and vomiting [1, 3, 4]. Diaphragmatic hernias rarely become symptomatic during pregnancy and are usually associated with a history of traumatic injury; they are rarely congenital. Common symptoms that lead the patient to hospital are sharp epigastric or left-side chest pain and unremitting nausea with vomiting. In cases presenting at more advanced stages, complications may develop such as gastric volvulus, spleen rupture, gastric or other intestinal obstructions, and/or perforation [4]. The diagnostic process of the current case, which presented with very severe epigastric pain, was delayed because x-ray evaluation was avoided because of the pregnancy. Nevertheless the clinical presentation of CDH during pregnancy can range from being totally asymptomatic to acute intestinal obstruction during any trimester of pregnancy [2,5,6]. Frontal and lateral chest radiography are appropriate imaging methods but thin-section CT scanning has higher sensitivity for these lesions. In the diagnosis, abdominal x-ray, fluoroscopy, USG, MRI, laparoscopy, and laparotomy can also be used. With the exception of CT, these imaging methods have a lower risk of exposure to the cumulative dose acceptable for the fetus. In situations where doubt remains, MR and USG are extremely helpful imaging methods. In such cases the imaging results may be misleading as the findings may mimic acute pulmonary problems such as cavitary pneumonia, pleural effusion, massive pneumothorax, or pneumatocele [7, 8].

However, on presentation at the Emergency Department, the diagnosis was not a priority and x-rays and tomography were not applied in order to protect the fetus from radiation. As the patient underwent cardiac arrest during the application of USG, the diagnosis was made in the ICU. In a case report by Hernandez-Aragon et al., USG and x-ray were applied to a pregnant patient for diagnostic purposes. As air-fluid level was seen over the diaphragm, the diagnosis was confirmed by MRI [9]. Nonetheless, there have been a few cases reported in the literature where x-ray and USG have been used on pregnant patients with a hernia.

The presence of a gravid uterus increases intra-abdominal pressure and increases the risk of complications such as incarceration, obstruction, and strangulation [1]. The current patient had recurrent vomiting which further increased the intra-abdominal pressure and subsequently increased the herniation of the abdominal contents into the thoracic cavity. This explained the occurrence of the sudden onset of respiratory distress, ischemia, and perforation of the gastric wall. Emergency intervention becomes mandatory in severely symptomatic patients as this condition is associated with high fetal and maternal loss [2,7]. Only about 100 to 150 reports of adult Bochdalek hernia can be found in the literature. The majority of these cases are incidental, asymptomatic, posterolateral diaphragmatic defects. The adult foramen of a Bochdalek hernia complicating pregnancy is a rare occurrence. A very high degree of awareness is needed for diagnosis as the symptoms produced by this hernia are also seen in a normal pregnancy. Clinicians should be aware of this rare condition in cases presenting with non-specific gastric symptoms.

Competing interests

The authors declare that they have no competing interests.

References

1. Losanoff JE, Sauter ER. Congenital posterolateral diaphragmatic hernia in an adult. *Hernia* 2004;8:83-5.
2. Spai S, Rao N, Balu K, Madhusudhanan J. Congenital Diaphragmatic Hernia Complicating Pregnancy: A Case Report. *Int J Gynaecol Obstet* 2007;9:1
3. Mullins ME, Stein J, Saini SS, Mueller PR. Prevalence of incidental Bochdalek's hernia in a large adult population. *AJR Am J Roentgenol* 2001;177:363-6.
4. Robb BW, Reed MF. Congenital diaphragmatic hernia presenting as splenic rupture in an adult. *Ann Thorac Surg* 2006;81:9-10.
5. Williams M, Appelboom R, McQuillan P. Presentation of diaphragmatic herniae during pregnancy and labour. *Int J Obstet Anesth* 2003;12:130-4.
6. Islah MAR, Jiffre D. A Rare Case of Incarcerated Bochdalek Diaphragmatic Hernia in a Pregnant Lady. *Med J Malaysia* 2010;65:75-6.
7. Muzzafar S, Swischuk LE, Jadhav SP. Radiographic findings in late-presenting congenital diaphragmatic hernia: helpful imaging findings. *Pediatr Radiol* 2012;42:337-42.
8. Adalı F, Adalı E. Gebelikte Tanısal Görüntüleme Yöntemlerinin Fetusa Etkisi. *Van Tıp Dergisi* 2008;15(2):64-9.
9. Hernández-Aragon M, Rodríguez-Lazaro L, Crespo-Esteras R, Ruiz-Campo L, Adiego-Calvo I, Campillos-Maza JM et al. Bochdalek Diaphragmatic Hernia Complicating Pregnancy in the third Trimester: Case Report. *Obstet Gynecol cases Rev* 2015;2:5.

How to cite this article:

Karabacak P, Osmanlioğlu HÖ, Ceylan BG, Yağlı MA, Yıldırım MK. Cardiac Arrest in a Pregnant Patient Diagnosed with Bochdalek Hernia. *J Clin Anal Med* 2016;7(5): 746-8.